The Simple Dental Extraction

Robert Eng, B.Sc., DMD, FRCD(C)
Clinical Instructor, Oral and Maxillofacial Surgery
Faculty of Dentistry, University of Toronto

Visiting Clinical Instructor
Department of Oral and Maxillofacial Surgery
Tufts University School of Dental Medicine

Indications for extractions

- Caries/nonrestorable tooth
- Necrotic pulp/active periapical infection
- Advanced periodontal disease
- “Cracked” tooth/Vertical Root Fracture
- Supernumerary teeth
- Impacted teeth
- Teeth associated with pathology
- Orthodontic reasons/malposed teeth
- Pending systemic considerations
- Financial issues

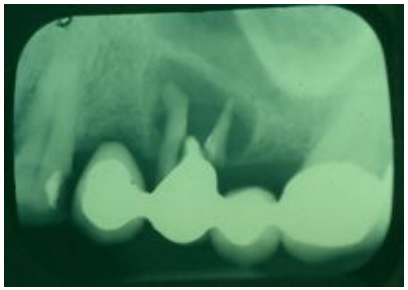

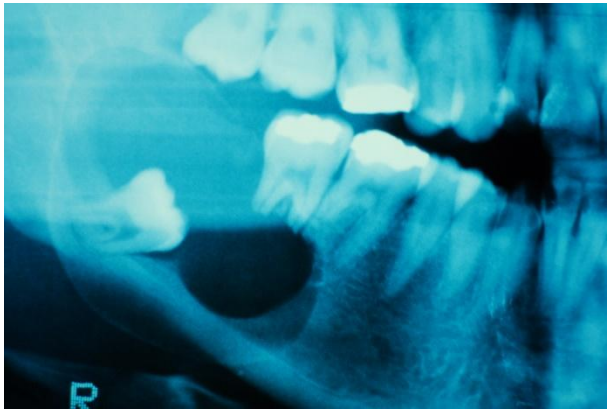

Robert Eng, B.Sc, DMD, FRCD(C)
Clinical Instructor, Oral and Maxillofacial Surgery
Faculty of Dentistry, University of Toronto

Indications for extractions

- Caries/nonrestorable tooth
- Necrotic pulp/active periapical infection
- Advanced periodontal disease
- “Cracked” tooth/Vertical Root Fracture
- Supernumerary teeth
- Impacted teeth
- Teeth associated with pathology
- Orthodontic reasons/malposed teeth
- Pending systemic considerations
    - Radiation therapy
    - Antiresorptive therapy
    - Chemotherapy
    - Immune system suppression/Transplant surgery
- Financial issues

“Whoopsee.”

Robert Eng, B.Sc, DMD, FRCD(C)
Clinical Instructor, Oral and Maxillofacial Surgery
Faculty of Dentistry, University of Toronto

Dental Extractions

Guiding principles

- The removal of a tooth creates a defect that cannot be restored 100 %. ***The result is permanent and not able to be reversed***
- The extraction is not an end in itself, it should rather be considered a means to an end – think of the next step
- The surrounding bone should be treated with the highest respect
- Minimize impact on the surrounding soft tissues

Robert Eng, B.Sc, DMD, FRCD(C)
Clinical Instructor, Oral and Maxillofacial Surgery
Faculty of Dentistry, University of Toronto

The simple dental extraction

Prerequisites for extraction:

- Proper Evaluation
  - Clinical
  - Radiographic
- Proper Consent
- Proper Instruments
- Proper technique
- Sufficient Skill
- Ability to perform proper follow-up
  and to take care of problems

Robert Eng, B.Sc, DMD, FRCD(C)
Clinical Instructor, Oral and Maxillofacial Surgery
Faculty of Dentistry, University of Toronto

The simple dental extraction

INSTRUMENTS

LA syringe and LA carpule(s)
Blade & Blade Handle
Periosteal elevator
Minnesota retractor
Elevator(s)
Appropriate forceps
Curette
Bone file
Rongeur
Haemostat
Needle driver
Tissue pickups
Suture
Scissors

Robert Eng, B.Sc, DMD, FRCD(C)
Clinical Instructor, Oral and Maxillofacial Surgery
Faculty of Dentistry, University of Toronto

The simple dental extraction

INSTRUMENTS

LA syringe and LA carpule(s)
Blade & Blade Handle
Periosteal elevator
Minnesota retractor
Elevator
Appropriate forceps
Curette
Bone file
Rongeur
Haemostat
Needle driver
Tissue pickups
Suture
Scissors

Robert Eng, B.Sc, DMD, FRCD(C)
Clinical Instructor, Oral and Maxillofacial Surgery
Faculty of Dentistry, University of Toronto

The simple dental extraction

Assistant's Instruments

- **Irrigating Syringe**
- **Irrigation Solution**
- **Suction -throat/mouth (Yankauer)**
- **-surgical (Frazer)**
- **Hand Mirror**
- **Gauze**
- **Scissors**



Robert Eng, B.Sc, DMD, FRCD(C)
Clinical Instructor, Oral and Maxillofacial Surgery
Faculty of Dentistry, University of Toronto

The simple dental extraction

Dental Elevators

Can be used to:

- **Luxate a tooth so as to give it initial mobility before proceeding to the forceps to remove a tooth or root**

Robert Eng, B.Sc, DMD, FRCD(C)
Clinical Instructor, Oral and Maxillofacial Surgery
Faculty of Dentistry, University of Toronto

The simple dental extraction

Dental Elevators

In order to avoid problems with the use of straight elevators certain rules *must* be followed

- **The straight elevator must be held in the dominant hand with the index finger placed along the blade, leaving its anterior end exposed, which is used to luxate the tooth or root (*finger acts as a stop*)**

- **This instrument must always be used Buccally - never on the lingual or palatal**

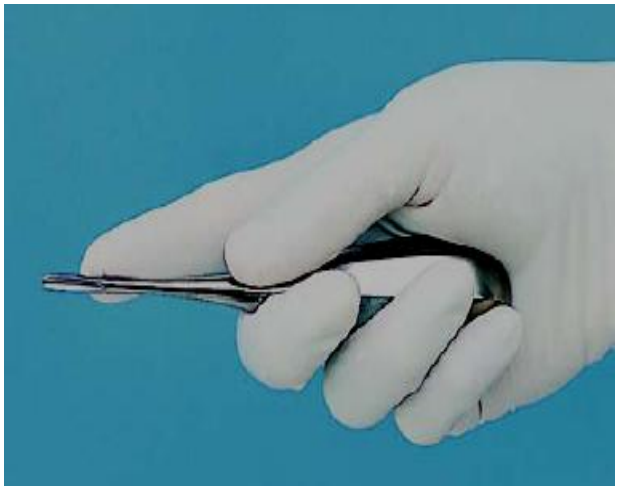

Robert Eng, B.Sc, DMD, FRCD(C)
Clinical Instructor, Oral and Maxillofacial Surgery
Faculty of Dentistry, University of Toronto

The simple dental extraction

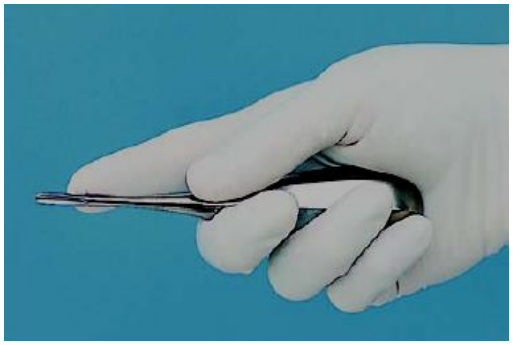

Dental Elevators

- The *concave surface of the blade must* be in contact with the mesial or distal surface of the tooth to be extracted

- The blade should be seated between the tooth and alveolar bone and *not the adjacent tooth*

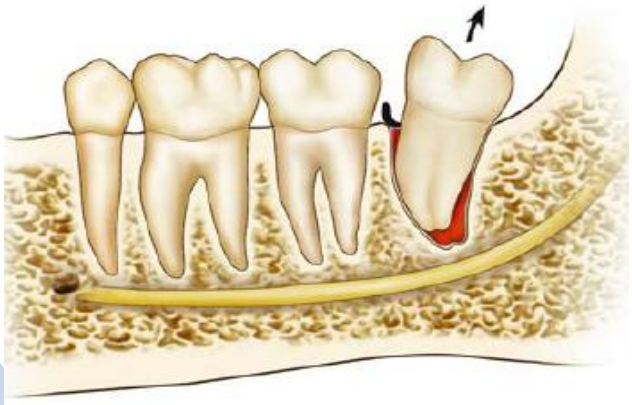

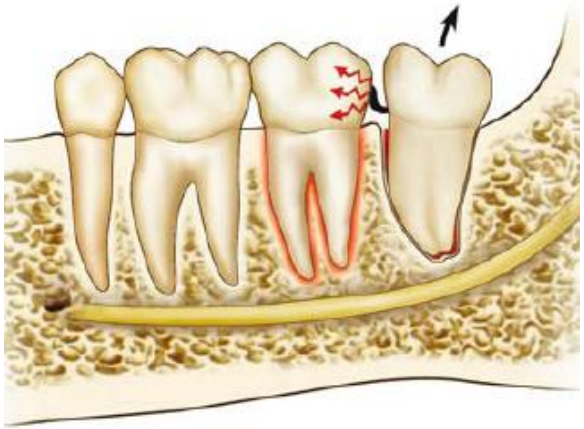

From Fragiskos

Robert Eng, B.Sc, DMD, FRCD(C)
Clinical Instructor, Oral and Maxillofacial Surgery
Faculty of Dentistry, University of Toronto

The simple dental extraction

Maxillary Forceps

In general, the beaks of maxillary extraction forceps are either parallel with their handle or offset at approximately a 45 degree angle or in a bayonet fashion. This allows better asses to posterior teeth without having to stretch the cheek

The handles for upper and lower forceps of both patterns can be straight and flat or curved on their edge or curved at the end

Robert Eng, B.Sc, DMD, FRCD(C)
Clinical Instructor, Oral and Maxillofacial Surgery
Faculty of Dentistry, University of Toronto

The simple dental extraction

Mandibular Forceps

The English pattern afford a greater mechanical advantage and better stabilization of the mandible when being used, but are often more difficult for posterior teeth in persons with small mouths where it is difficult to retract the cheek

- **With English lower forceps the beaks are in the same plane as the handle**

With American pattern forceps the beak is at right angles to the plane of the handle.

Robert Eng, B.Sc, DMD, FRCD(C)
Clinical Instructor, Oral and Maxillofacial Surgery
Faculty of Dentistry, University of Toronto

The simple dental extraction

Gomphosis Components

- Cementum
- Periodontal fibers
- Lamina dura

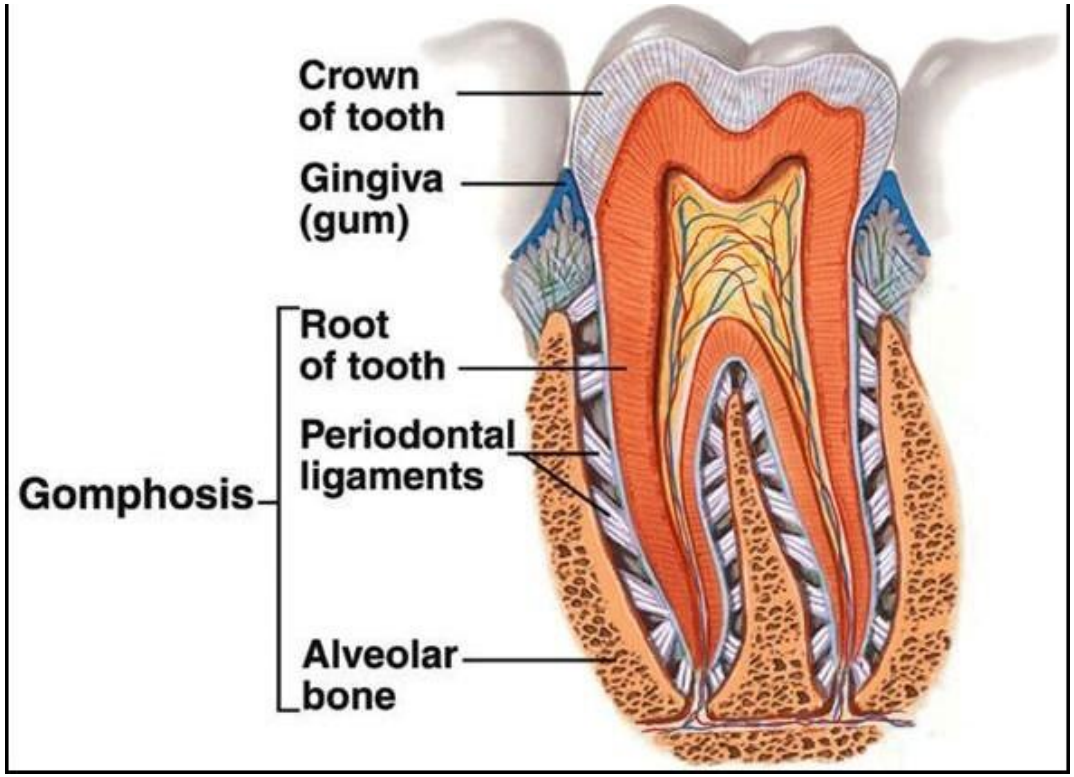

Robert Eng, B.Sc, DMD, FRCD(C)
Clinical Instructor, Oral and Maxillofacial Surgery
Faculty of Dentistry, University of Toronto

The simple dental extraction

Overcoming Gomphosis !!

- Create microfractures in the supporting bone causing an enlargement of the socket
- This enlargement leads to the stretching and breaking of the collagen fibres suspending the tooth
- All of the above are achieved with the use of a controlled force that does not cause excessive damage to the surrounding tissues

Robert Eng, B.Sc, DMD, FRCD(C)
Clinical Instructor, Oral and Maxillofacial Surgery
Faculty of Dentistry, University of Toronto

The simple dental extraction

Assessing the difficulty

Clinical evaluation

Access to the area

Condition of the crown

Mobility

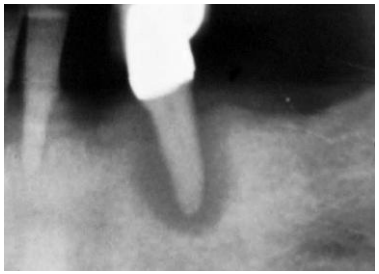

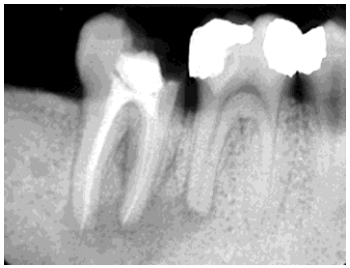

Robert Eng, B.Sc, DMD, FRCD(C)
Clinical Instructor, Oral and Maxillofacial Surgery
Faculty of Dentistry, University of Toronto

The simple dental extraction

Assessing the difficulty

Radiographic evaluation **No extraction without radiographs!**

Number, shape, morphology of roots

Robert Eng, B.Sc, DMD, FRCD(C)
Clinical Instructor, Oral and Maxillofacial Surgery
Faculty of Dentistry, University of Toronto

The simple dental extraction

Assessing the difficulty

Radiographic evaluation **No extraction without radiographs!**

Assessing the path of withdrawal

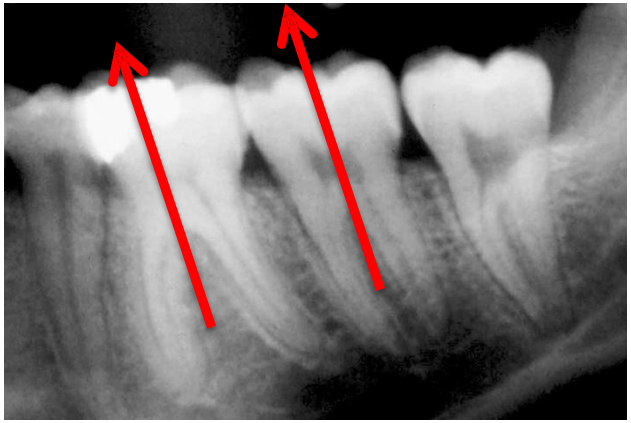

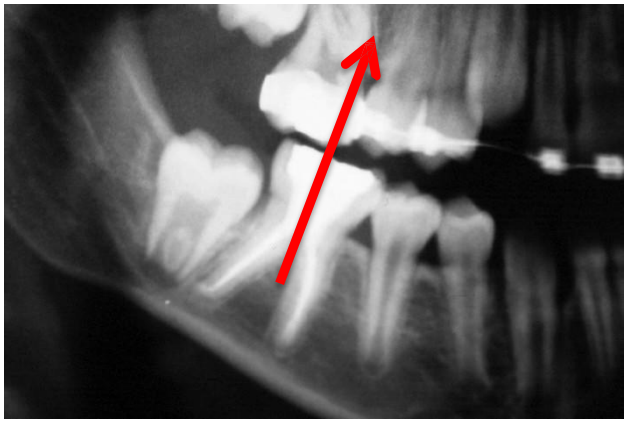

Robert Eng, B.Sc, DMD, FRCD(C)
Clinical Instructor, Oral and Maxillofacial Surgery
Faculty of Dentistry, University of Toronto

The simple dental extraction

Assessing the difficulty

Radiographic evaluation **No extraction without radiographs!**

Relationship to surrounding anatomy

Robert Eng, B.Sc, DMD, FRCD(C)
Clinical Instructor, Oral and Maxillofacial Surgery
Faculty of Dentistry, University of Toronto

The simple dental extraction

Assessing the difficulty

Radiographic evaluation **No extraction without radiographs!**

Previous RCT

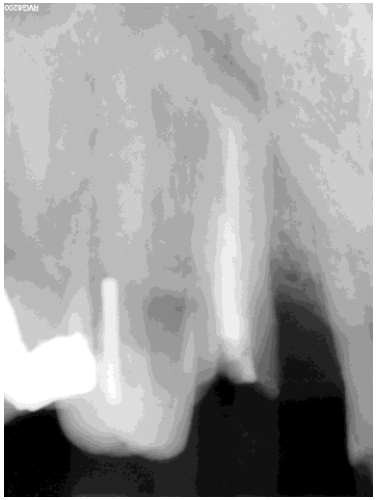

Robert Eng, B.Sc, DMD, FRCD(C)
Clinical Instructor, Oral and Maxillofacial Surgery
Faculty of Dentistry, University of Toronto

The simple dental extraction

Sequence of steps

- Obtain informed consent
- Achieve local anaesthesia
- Sever soft tissue attachment
- Dental elevator
- apply forceps – grasp alveolar process
- loosen/luxate/tractional force on tooth
- post extraction socket care
  - apply pressure to achieve hemostasis
  - discharge patient with instructions

Robert Eng, B.Sc, DMD, FRCD(C)
Clinical Instructor, Oral and Maxillofacial Surgery
Faculty of Dentistry, University of Toronto

The simple dental extraction

Local Anesthesia – Mandible

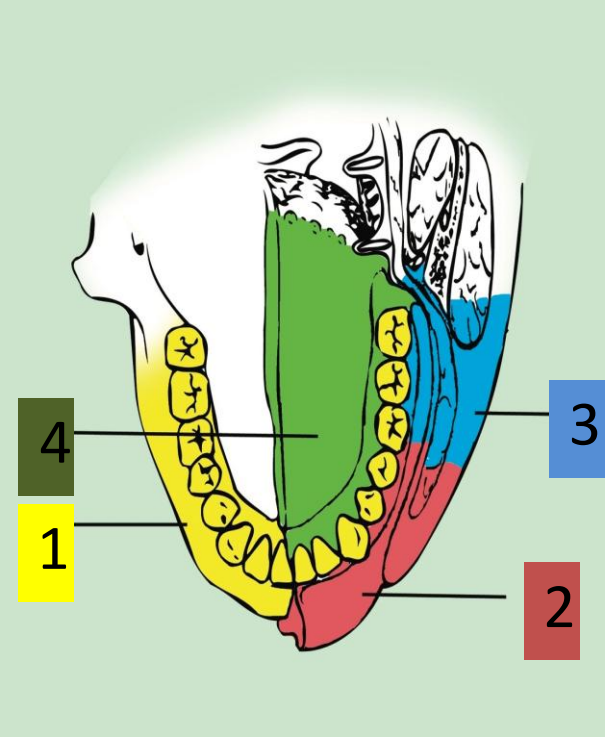

1 IAN block

2 IAN block

3 Long buccal n. block

4 Lingual n. block

Robert Eng, B.Sc, DMD, FRCD(C)
Clinical Instructor, Oral and Maxillofacial Surgery
Faculty of Dentistry, University of Toronto

The simple dental extraction

Local Anesthesia – Mandible

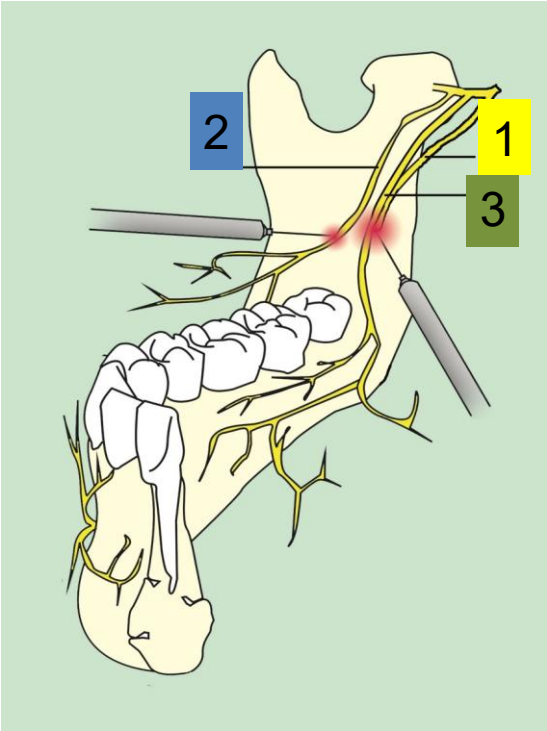

1 IAN block

2 Long buccal n. block

3 Lingual n. block

Robert Eng, B.Sc, DMD, FRCD(C)
Clinical Instructor, Oral and Maxillofacial Surgery
Faculty of Dentistry, University of Toronto

The simple dental extraction

Local Anesthesia – Mandible

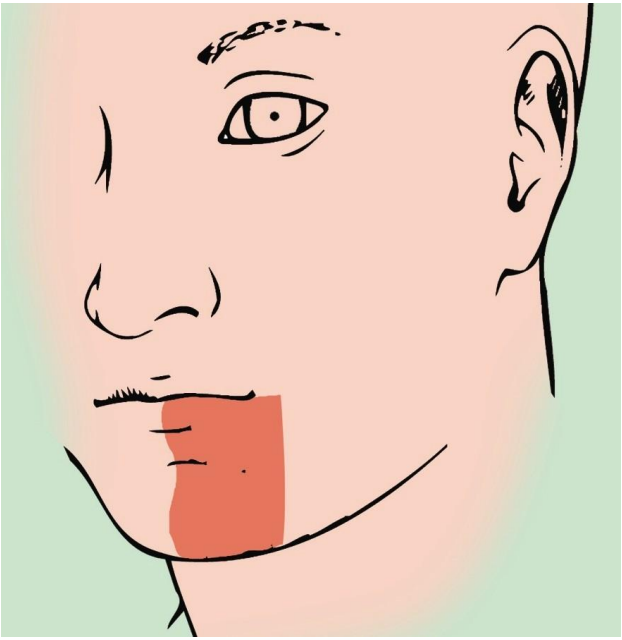

The hallmark of an effective IAN block
Numbness of the lip/chin area

Robert Eng, B.Sc, DMD, FRCD(C)
Clinical Instructor, Oral and Maxillofacial Surgery
Faculty of Dentistry, University of Toronto

The simple dental extraction

Adverse Reactions to Local Anaesthesia

Table 3 **Adverse reactions of commonly used local anesthetics**

Psychogenic
Syncope (most common)
Hyperventilation
Nausea, vomiting
Alterations in heart rate or blood pressure
Mimicking of an allergic reaction
Allergic (potential allergens)
Esters (true amide allergy is very rare)
Metabisulfite (present with epinephrine and with levonordefrin)
Methylparaben (no longer added to dental cartridges)
Toxic effects
Primarily neurologic signs
May initially manifest as sedation, lightheadedness, slurred speech, mood alteration, diplopia, sensory disturbances, disorientation, muscle twitching
Higher blood levels may result in tremors, respiratory depression, tonic–clonic seizures
If severe, may result in coma, respiratory arrest, cardiovascular collapse
Methemoglobinemia
Associated with prilocaine, articaine, benzocaine
Paresthesia
Apparently more common with articaine and prilocaine

Malamed Handbook of Local Anesthesia

Robert Eng, B.Sc, DMD, FRCD(C)
Clinical Instructor, Oral and Maxillofacial Surgery
Faculty of Dentistry, University of Toronto

The simple dental extraction

Severing the soft tissue attachment

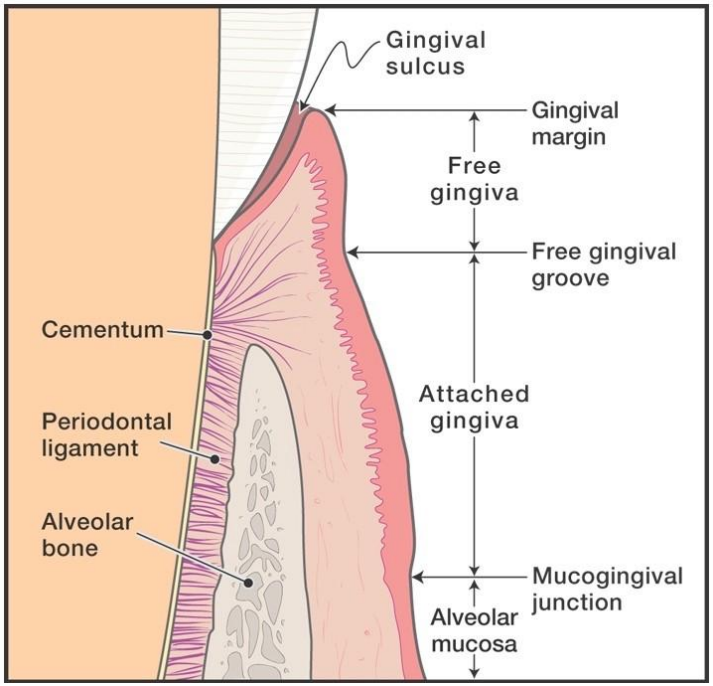

Robert Eng, B.Sc, DMD, FRCD(C)
Clinical Instructor, Oral and Maxillofacial Surgery
Faculty of Dentistry, University of Toronto

The simple dental extraction

Positioning the patient

Angle between upper arm and forearm at 100°+ ALWAYS!!!

Back of chair at ~100°+ for maxilla

Back of chair at ~90°+ for mandible

Patient's head extended – "chin up" for maxilla

Operator's back straight !!!

Robert Eng, B.Sc, DMD, FRCD(C)
Clinical Instructor, Oral and Maxillofacial Surgery
Faculty of Dentistry, University of Toronto

The simple dental extraction

Operator Position

Maxilla

- Position yourself at the 7-8 o'clock position (for right handed operators) or 4-5 o'clock position (for left handed for the removal of the maxillary teeth.
- If you use the forceps back handed, stand at the 11 o'clock position

Mandible

- The operator should position to the front of the patient with the forceps in the right hand and the left hand supporting the mandible and soft tissues
- In this position, the operator has a relatively straight back, and can look down on the tooth. The forceps are applied with the right hand and the mandible supported to minimize the pressure on the TMJ

Robert Eng, B.Sc, DMD, FRCD(C)
Clinical Instructor, Oral and Maxillofacial Surgery
Faculty of Dentistry, University of Toronto

The simple dental extraction

Extraction mechanics
(Ultimate goal is the expansion of the socket)

Application of the forceps

Beaks parallel to the long axis of tooth

Beaks placed as apical as possible beyond gingival margin

Eccentric or shallow placement will create difficulties

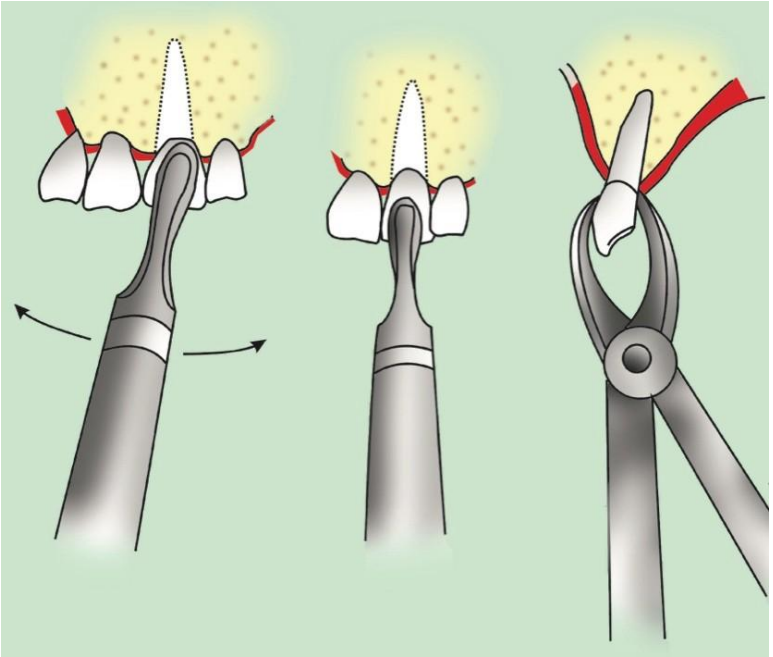

Robert Eng, B.Sc, DMD, FRCD(C)
Clinical Instructor, Oral and Maxillofacial Surgery
Faculty of Dentistry, University of Toronto

The simple dental extraction

Extraction mechanics
(Ultimate goal is the expansion of the socket)

Application of the forceps

The forceps applies

Axial force
Lateral forces (Buccal - lingual/palatal luxation)
Rotational force
Tractional force

Robert Eng, B.Sc, DMD, FRCD(C)
Clinical Instructor, Oral and Maxillofacial Surgery
Faculty of Dentistry, University of Toronto

The simple dental extraction

Extraction mechanics
(Ultimate goal is the expansion of the socket)

Application of the forceps

Axial force

Expands socket at top
Guarantees low center of rotation
Maintains “grip” on tooth

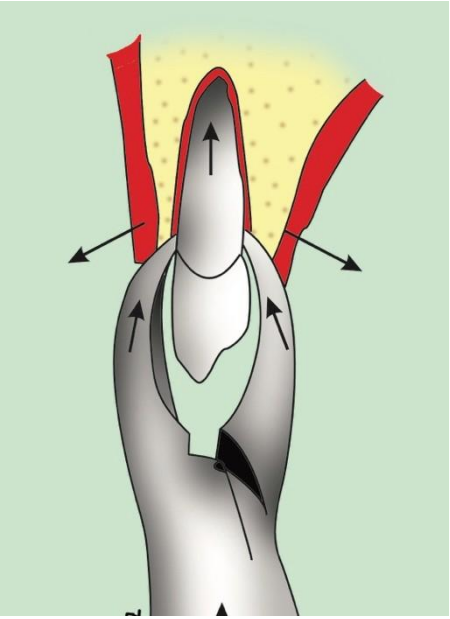

Robert Eng, B.Sc, DMD, FRCD(C)
Clinical Instructor, Oral and Maxillofacial Surgery
Faculty of Dentistry, University of Toronto

The simple dental extraction

Extraction mechanics
(Ultimate goal is the expansion of the socket)

Application of the forceps

Lateral forces
(Buccal - lingual/palatal luxation)

Socket wall expansion

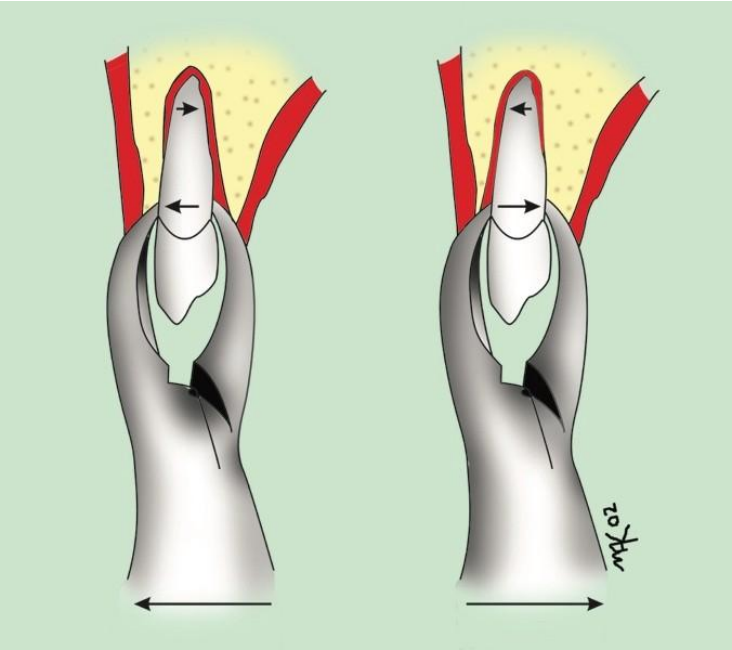

Robert Eng, B.Sc, DMD, FRCD(C)
Clinical Instructor, Oral and Maxillofacial Surgery
Faculty of Dentistry, University of Toronto

The simple dental extraction

Extraction mechanics
(Ultimate goal is the expansion of the socket)

Application of the forceps

Lateral forces
(Buccal - lingual/palatal luxation)

Socket wall expansion

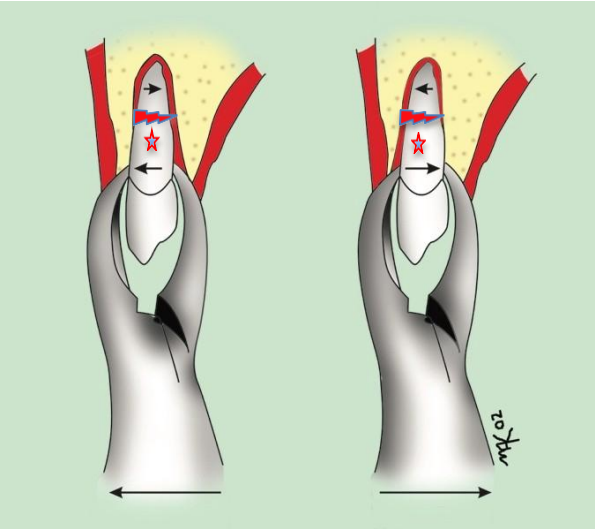

Shallow rotation point predisposes to root fracture

Nick Katsikeris DDS., Dr.Dent., FICD
Assistant Professor
Clinical Instructor, Oral and Maxillofacial Surgery
Faculty of Dentistry, University of Toronto

The simple dental extraction

Extraction mechanics
(Ultimate goal is the expansion of the socket)

Application of the forceps

Rotational forces

- Only on single-rooted teeth with straight root
- Only when tooth is loose enough
- Deliver tooth

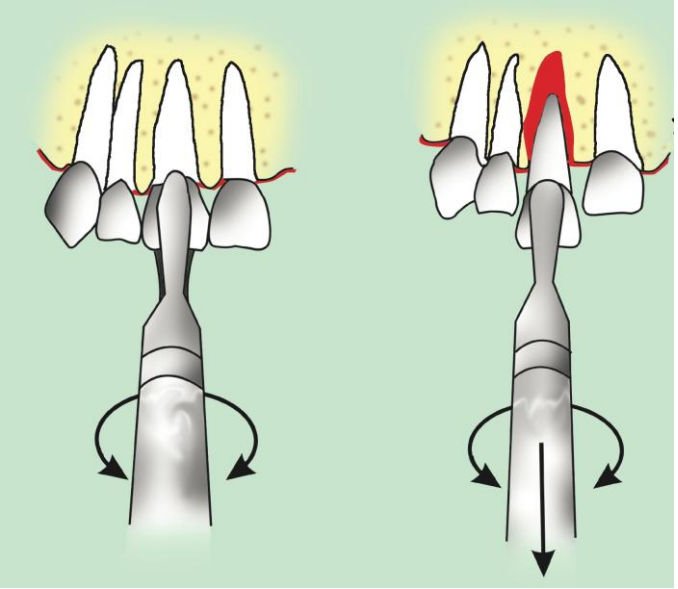

Robert Eng, B.Sc, DMD, FRCD(C)
Clinical Instructor, Oral and Maxillofacial Surgery
Faculty of Dentistry, University of Toronto

The simple dental extraction

Extraction mechanics
(Ultimate goal is the expansion of the socket)

Application of the forceps

Tractional forces (straight pulling)

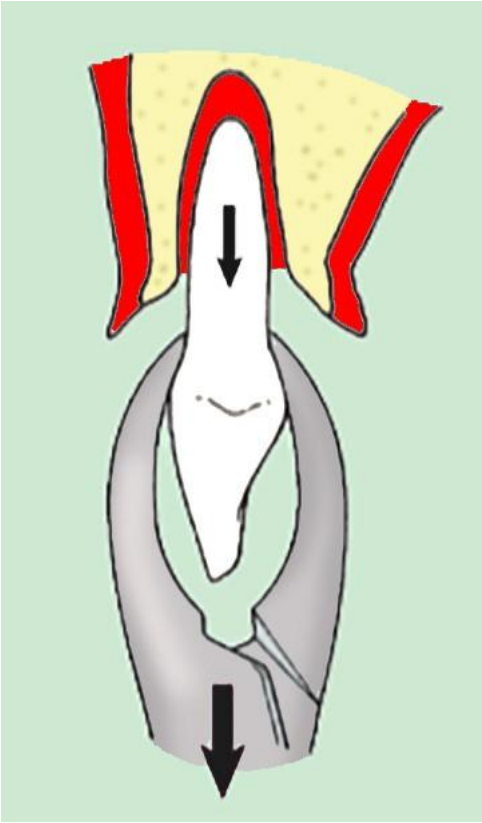

Only when tooth is very loose

Robert Eng, B.Sc, DMD, FRCD(C)
Clinical Instructor, Oral and Maxillofacial Surgery
Faculty of Dentistry, University of Toronto

The simple dental extraction

Extraction mechanics
(Ultimate goal is the expansion of the socket)

Application of the forceps

Tractional forces (straight pulling)



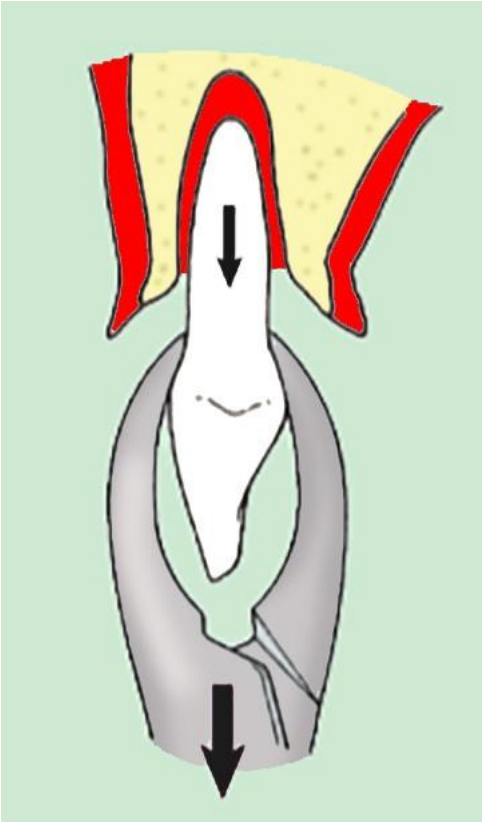

Robert Eng, B.Sc, DMD, FRCD(C)
Clinical Instructor, Oral and Maxillofacial Surgery
Faculty of Dentistry, University of Toronto

The simple dental extraction

Luxate/loosen/traction tooth

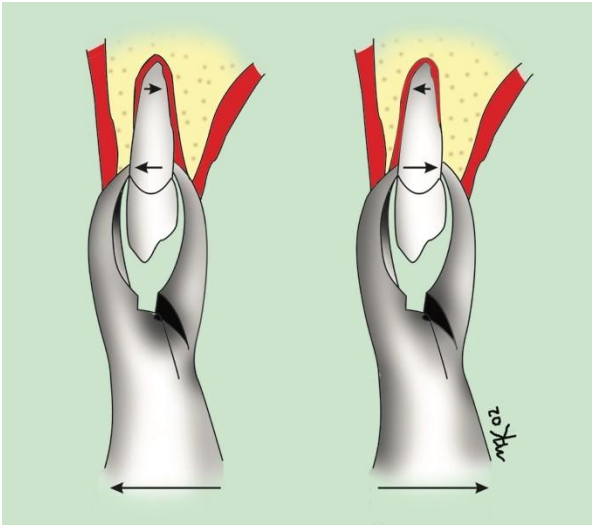

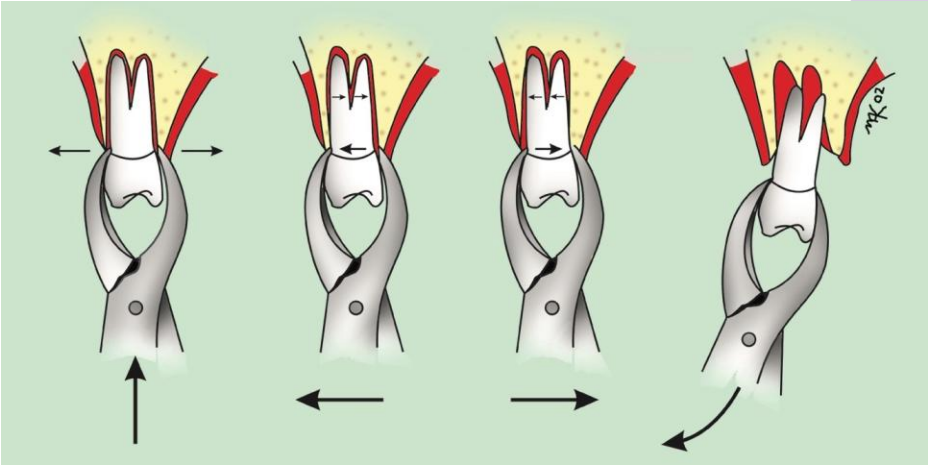

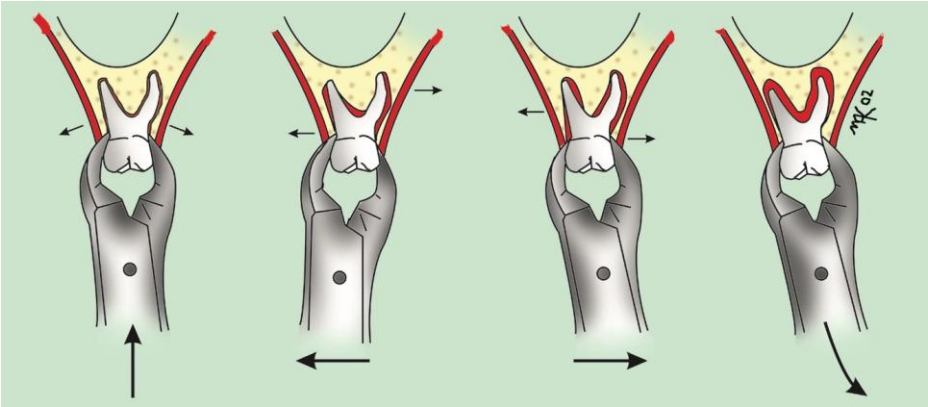

Robert Eng, B.Sc, DMD, FRCD(C)
Clinical Instructor, Oral and Maxillofacial Surgery
Faculty of Dentistry, University of Toronto

The simple dental extraction

Dental Forceps

Once the patient is in position and the operator has confirmed adequate anesthesia, then the luxator can be applied apically alongside the mesial, distal, and palatal aspects of the tooth. The forceps are then applied, and the forceps blades are pushed apically for 10 seconds as far as possible. The right arm of the operator will be almost straight, though with a slight bend at the elbow. After 10 seconds the forceps are rotated 15º and again held for 10 seconds. Then the forceps are turned in the opposite direction. If at this point the tooth is not yielding, then simply repeating the maneuver will continue to disrupt the periodontal membrane and ultimately rend it so as to loosen the tooth.

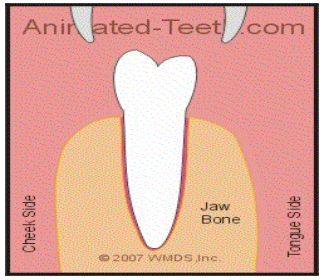

Robert Eng, B.Sc, DMD, FRCD(C)
Clinical Instructor, Oral and Maxillofacial Surgery
Faculty of Dentistry, University of Toronto

The simple dental extraction

Luxate/loosen/traction tooth

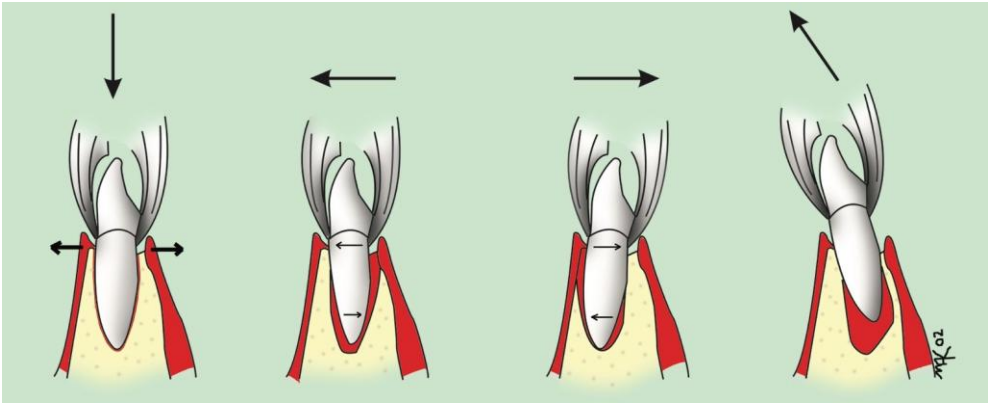

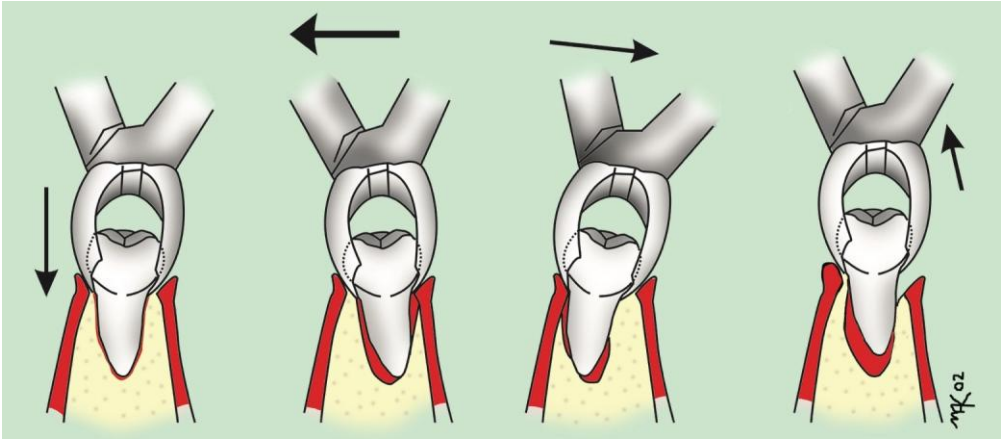

Robert Eng, B.Sc, DMD, FRCD(C)
Clinical Instructor, Oral and Maxillofacial Surgery
Faculty of Dentistry, University of Toronto

The simple dental extraction

The cowhorn forceps

Two pointed beaks entering the bifurcation between tooth and alveolar process

Beaks act as a wedge pushing the tooth away from socket

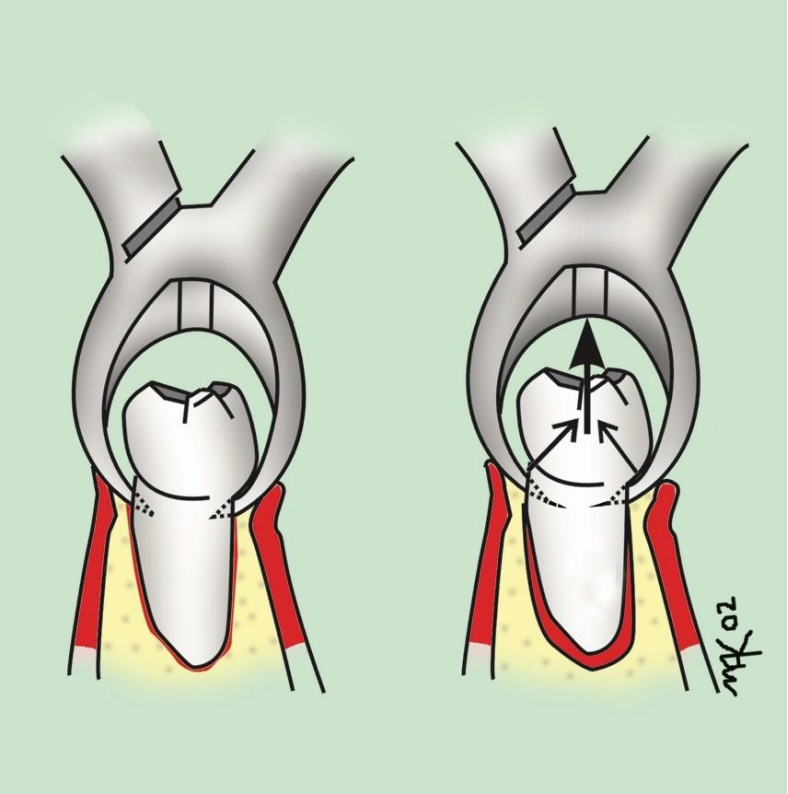

Robert Eng, B.Sc, DMD, FRCD(C)
Clinical Instructor, Oral and Maxillofacial Surgery
Faculty of Dentistry, University of Toronto

The simple dental extraction

Post extraction socket care

- debride if necessary
- palpate for sharp bony edges
- compress socket
- Make sure bleeding has stopped

Robert Eng, B.Sc, DMD, FRCD(C)
Clinical Instructor, Oral and Maxillofacial Surgery
Faculty of Dentistry, University of Toronto

The simple dental extraction

Post extraction socket care

Robert Eng, B.Sc, DMD, FRCD(C)
Clinical Instructor, Oral and Maxillofacial Surgery
Faculty of Dentistry, University of Toronto